

[Gift of Life New England](#)

Gift of Life 7260

Gift of Life 7470

LaJolla Sunrise Rotary Club District
5340

[Gift of Life International](#)

Gift of Life







Rotary District 7980
Gift of Life Foundation

Rotary Club of Monterrey, Mexico

Gift of Life Mexico & USA

“We have no borders....we just want to fix the broken hearts of our kids”

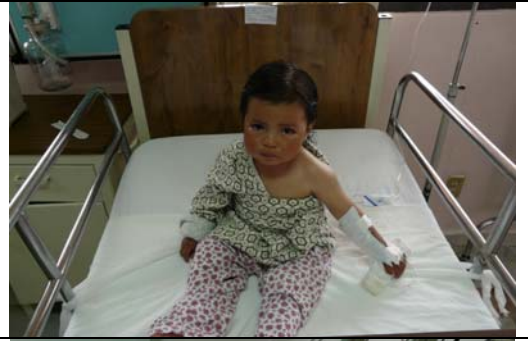Updated: 7 September 2008

<p>Gustavo Solís Castelar Age 6 years Xonacatlán</p> <p>Surgical Procedure 25 august 2008 Closure ASD (Atrial Septal Defect)</p>	 A photograph of a young boy lying in a hospital bed. He is wearing a white diaper and has several medical sensors and wires attached to his chest and arms. A person's hand is visible near his head.
<p>Aída Aguilar Galván Age 1 ½ years Temoaya</p> <p>Surgical Procedure 25 august 2008 Closure of the PDA (Patent Ductus Arteriosus)</p>	 A photograph of a baby lying in a hospital bed. The baby is wearing a white diaper and has medical sensors and wires attached to their chest and arms.
<p>María Guadalupe Monroy Monroy Age 6 years San Andrés Timilpan</p> <p>Surgical Procedure 26 august 2008 Closure of ASD (Atrial Septal Defect)</p>	 A photograph of a young girl lying in a hospital bed. She is wearing a white diaper and has several medical sensors and wires attached to her chest and arms.
<p>Isaac López Palma Age 5 years</p> <p>Surgical Procedure 26 august 2008 Closure of the PDA (Patent Ductus Arteriosus)</p>	 A photograph of a young boy lying in a hospital bed. He is wearing a white diaper and has several medical sensors and wires attached to his chest and arms.

<p>Alejandro Blancas Vega Age 6 years Santiago Tianguistengo</p> <p>Surgical Procedure 26 august 2008 Closure of the PDA (Patent Ductus Arteriosus)</p>	
<p>María Fernanda García Sandoval Age 18 months Tenango del Valle</p> <p>Surgical Procedure 26 august 2008 Closure of the PDA (Patent Ductus Arteriosus)</p>	
<p>José Luis Alvarado López Age 8 years Toluca</p> <p>Surgical Procedure 27 august 2008 Closure ASD and VSD PULMONARY HIPERTENSION (Atrial Septal Defect and Ventricular Septal Defect)</p>	
<p>Aimé Reza Pérez Age 3 years Toluca</p> <p>Surgical Procedure 27 august 2008 Closure of the PDA (Patent Ductus Arteriosus)</p>	
<p>Flavio Heras Villegas 13 years San Mateo Atenco</p> <p>Surgical Procedure 28 august 2008 Closure of ASD (Atrial Septal Defect)</p>	

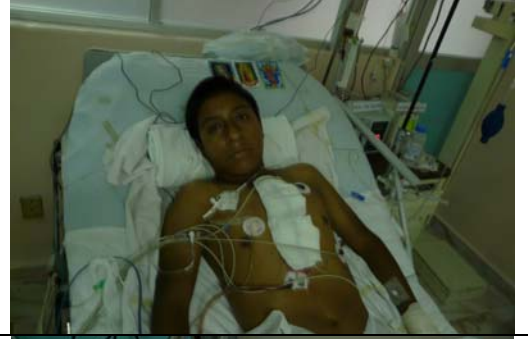Evelyn Quintana Oro
Age 18 months
San Miguel Hojas Anchas

Surgical Procedure
28 august 2008
Closure of the PDA (Patent Ductus Arteriosus)



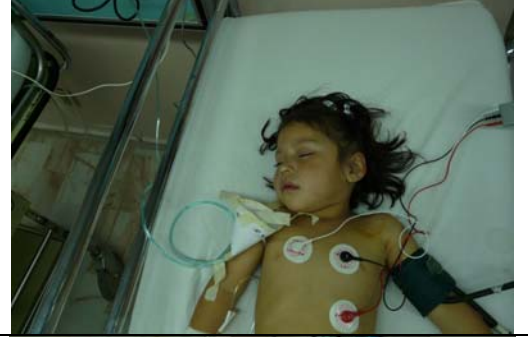José Guadalupe Lara Flores
Age 15 y
Meteppec

Surgical Procedure
29 august 2008
Closure of ASD (Atrial Septal Defect)



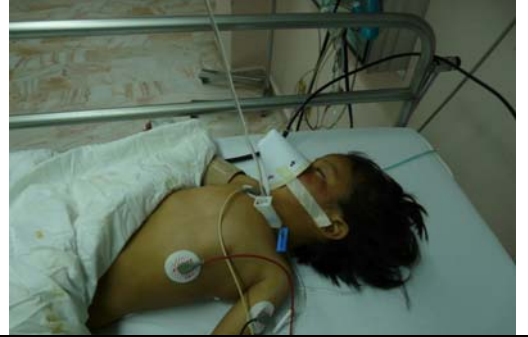Daysi Adamari Cerritos Paniagua
Age 3 years
Zinacantepec

Surgical Procedure
29 august 2008
Closure of the PDA (Patent Ductus Arteriosus)



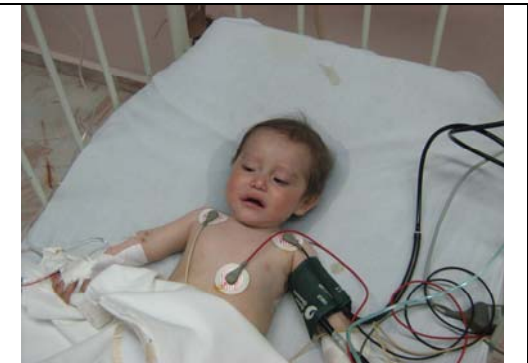Dulce Rivera Cristostomo
Age 2 ½ years
San Felipe del Progreso

Surgical Procedure
29 august 2008
Closure of the PDA (Patent Ductus Arteriosus)



Daniel Velazquez Barrera
Age: 11 months
San Miguel Balderas

Surgical Procedure:
11 June 2008: Closure of the PDA (Patent Ductus Arteriosus)

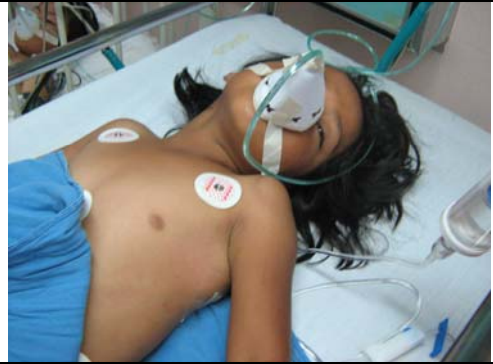

Dense Rangel Aguilar

Age: 4 years
San Joaquin Del Monte

Surgical Procedure:

11 June 2008: Closure of the PDA (Patent Ductus Arteriosus)

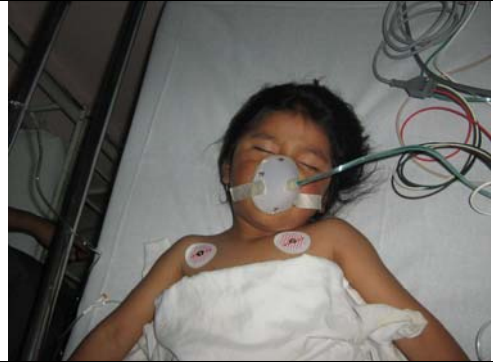

Itzel Gonzalez Eligio

Age: 4 years
Santa Ana Ixtlahuaca

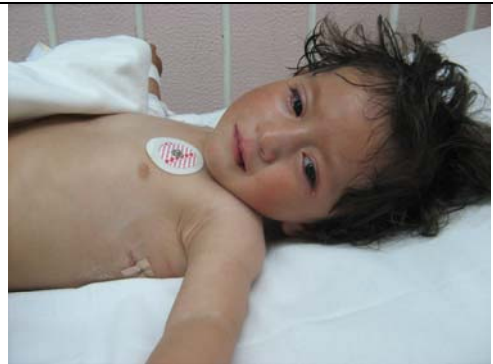Surgical Procedure:

11 June 2008: Closure of the PDA (Patent Ductus Arteriosus)



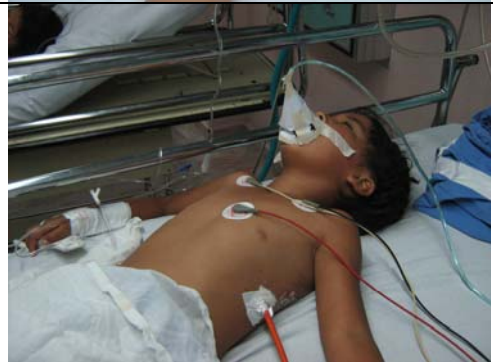Karen Dense Cardenas Luna
Age: 1 year 7 months
Tlacotepec

11 June 2008: Closure of the PDA (Patent Ductus Arteriosus)



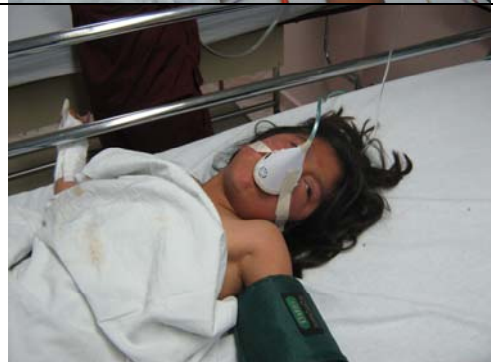Margarita Torres Mena
Age: 7 years
Santa Ana Ixtlahuaca

11 June 2008: Closure of the PDA (Patent Ductus Arteriosus)



Yaneth Galindo Cruz
Age: 8 years 6 months
Jiquipilco

11 June 2008: Closure of the PDA (Patent Ductus Arteriosus)

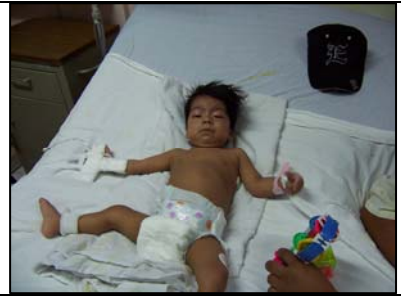

Jenifer Guadalupe Hernandez Velazquez

Age: 7 months
Arcelia, Guerrero

Surgical Procedure:

12 May 2008: Closure of the PDA (Patent Ductus Arteriosus)

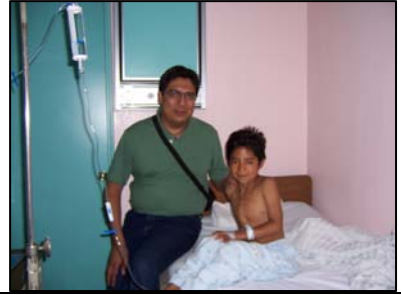

Omar Daniel Maya

Age: 8 Years
Almoloya de Juarez, Mexico

Surgical Procedure:

13 May 2008: Closure of the PDA (Patent Ductus Arteriosus)

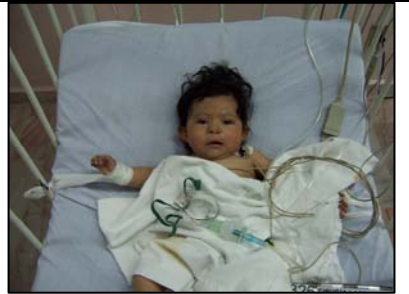

Joseline Naomi Sanchez Barcenas

Age: 11 months
Ecatepec, Mexico

Surgical Procedure:

13 May 2008: Closure of the PDA (Patent Ductus Arteriosus)

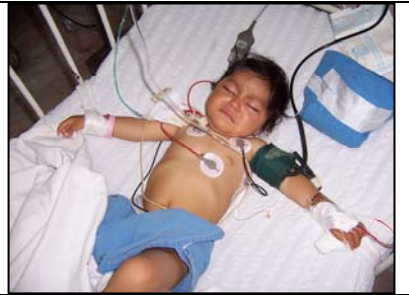

Maria Daniela Antonio Leon

Age: 11 Months
San Felipe del Progreso, Mexico

Surgical Procedure:

13 May 2008: Closure of the PDA (Patent Ductus Arteriosus)

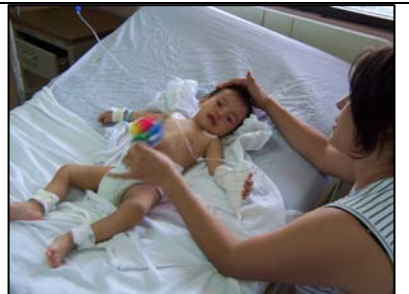

Ariana Martinez Gonzaga

Age: 22 Months
Atacomulco, Mexico

Surgical Procedure:

13 May 2008: Closure of the PDA (Patent Ductus Arteriosus)



Aron Edmundo Paredes Espinosa

Age: 9 months
Atlacomulco, Mexico

Surgical Procedure:

12 May 2008: Closure of the PDA (Patent Ductus Arteriosus)

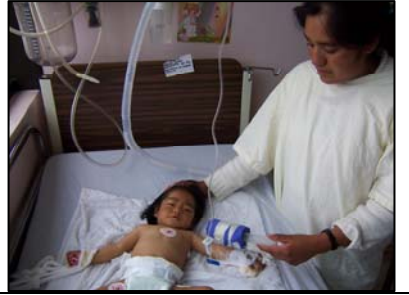

Abril Garcia Torres

Age: 10 months
San Felipe del Progreso, Mexico

Surgical Procedure:

12 May 2008: Closure of the PDA (Patent Ductus Arteriosus)

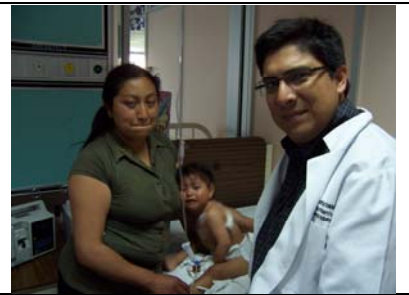

Mariela Isabel Pavon Contreras

Age: < 1 yr.
Ocoyoacac, Mexico

Surgical Procedure:

12 May 2008: Closure of the PDA (Patent Ductus Arteriosus)

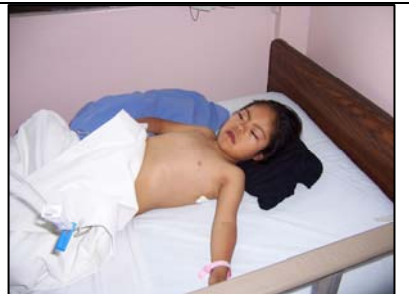

Maria Guadalupe Hernandez German

Age: 5 years
Toluca, Mexico

Surgical Procedure:

12 May 2008: Closure of the PDA (Patent Ductus Arteriosus)

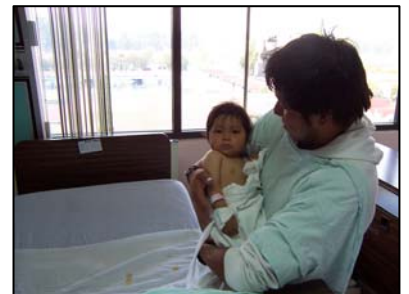

Itzel Valeria Alvarez Lopez

Age: 11 Months
Valle de Bravo, Mexico

Surgical Procedure:

12 May 2008: Closure of the PDA (Patent Ductus Arteriosus)

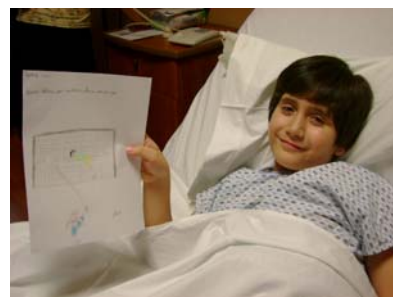

Saul Isaac Perez

Age: 11
Tijuana, B.C. Mexico

Surgical Procedure:

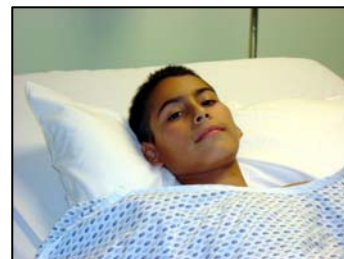8/25/07 Closure of the intraventricular septal defect



Mario Ari Ramirez

Age 14
Mexicali Mexico

Surgical Procedure: 8/25/07 Closure of the arterial septal defect.



Maria Guadalupe Garcia De Jesus

Age 5
Cuexcontintlan, Edo. De Mexico

Surgical Procedure:

6/23/07 Closure of the PDA (Patent Ductus Arteriosus)




Arantza Gomez Jimenez

Age 2
San Mateo, Mexico

Surgical Procedure:

6/23/07 Closure of the PDA (Patent Ductus Arteriosus)

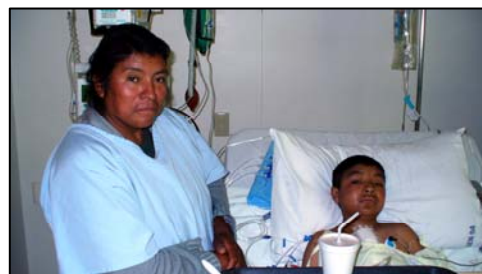

Salvador Casimiro Casimiro

Age: 12
Jocotitlan, Mexico

Surgical Procedure:

10/27/07 Closure of the Aterial Septal Defect at Hospital San Jose



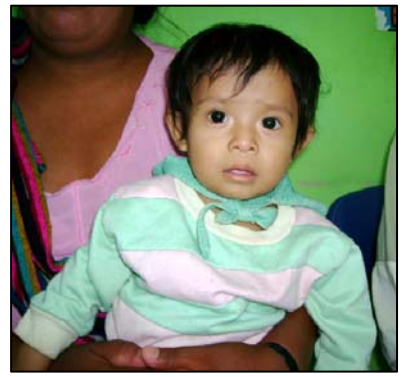Maria Guadalupe Diaz Lopez

Age 1

Palenque, Chiapas

Surgical Procedure:

6/23/07 Closure of the PDA (Patent Ductus Arteriosus)



Aldo Alonso Rodriguez Tovar

Age 5

Monterrey, N.L. Mexico

Surgical Procedure:

11/17/07 Closure of the Ventricular & arterial septal defects.

